

Dermatomyositis Complicated Case with Muscular Hematoma

Kas Hematomuyla Komplike Dermatomiyoitli Olgu

Nilüfer Aylanç¹, Mustafa Reşorlu¹, Gürhan Adam¹, Ozan Karatağ¹, Fatma Uysal¹, Zerrin Öğretmen²

¹ Çanakkale Onsekiz Mart Üniversitesi Tıp Fakültesi Radyoloji Anabilim Dalı, Çanakkale.

² Çanakkale Onsekiz Mart Üniversitesi Tıp Fakültesi Dermatoloji Anabilim Dalı, Çanakkale.

Abstract

A 62 years old woman diagnosed with dermatomyositis went to MRI examination because of her left hip pain and on her imaging findings the high signal intensities on iliopsoas, proximal thigh muscles and some pelvic muscles we determined, in addition there was no any contrast enhancement. However, there are haemorrhages on her left psoas muscle. We evaluated these findings as haemorrhagic myositis, which is the rare situation seen during follow up such these patients.

Keywords: Dermatomyositis, haemorrhage, magnetic resonance images, hip pain.

Özet

dermatomyositis; haemorrhage; magnetic resonanDermatomiyoit tanısı konmuş 62 yaşındaki kadın hasta sol kalça ağrısı nedeni ile çekilem MR görüntüleme sol iliopsoas, proksimal uyluk kasları ve bazı pelvik kaslarda yüksek sinyal artışı saptandı ek olarak kontrast farkı yoktu. Ancak hastanın sol iliopsoas kasında kanama alanları saptandı. Biz bu hastaların takibinde hemorajik miyoitinin nadir bir durum olduğu için sunmayı planladık.

Anahtar kelimeler: Dermatomiyoit, hemoraji, manyetik rezonans görüntüleme, kalça ağrısı.

Introduction

Dermatomyositis is an inflammatory myopathy with characteristic skin lesions, typically heliotrope (slightly cyanotic erythema) on the malar and supraorbital areas of the face and other areas, including the shoulders, upper back, and upper arms [1]. Dermatomyositis may be associated with systemic manifestations, including restrictive and interstitial lung disease and cardiomyopathy. The inflammatory mechanism is attributed to a primary T-helper-cell-dependent, B-cell-mediated, local humeral immune mechanism, which causes vascular occlusion and capillary obliteration with ischemic change in the skin and muscle [1,2]. There have been a few

reports of dermatomyositis causing hemorrhagic myositis [3-5].

Case

We present a 62 years old female patient diagnosed with dermatomyositis was administered corticosteroid in the department of dermatology. During her hospitalization she complained with acute onset pain on her left hip localization and examined with magnetic resonance imaging (MRI). On her first MRI, on fat-suppressed T2-weighted images high signal intensities on iliopsoas and proximal thigh muscles bilaterally and some pelvic muscles almost in both sides (Figure 1). After

Sorumlu yazar / Corresponding Author: Nilüfer Aylanç

Adres: Çanakkale Onsekiz Mart Üniversitesi Tıp Fakültesi Radyoloji Anabilim Dalı, Çanakkale.

E-mai: niluferaylanc@gmail.com

Geliş Tarihi / Received: 10.06.2014

Kabul Tarihi / Accepted: 23.02.2015

4 days, her MRI examination was repeated but this time with contrast (Figure 2), if there is any formation of abscess because at the same time she had 22,6 (103/mm³) white blood cells in the laboratory tests. On the last imaging, there was not seen any abscess, but there

was a hemorrhagic signals on left psoas muscle. Also other findings about myositis had been minimal regressed. Between the two MRI examinations, also her hemoglobin decreased from 10,6 gr/dl to 8,6 gr/dl. This was supporting for hemorrhage in psoas muscle.

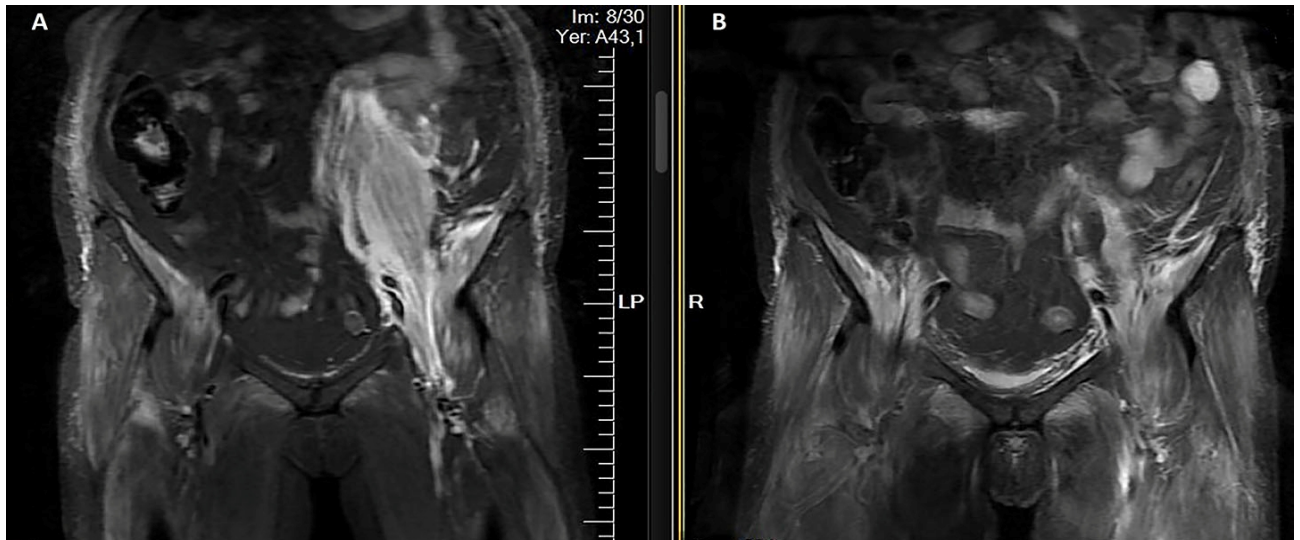


Figure 1. Coronal fat-suppressed T2-weighted images A and B; high signals in pelvic and proximal thigh muscles indicates myositis.

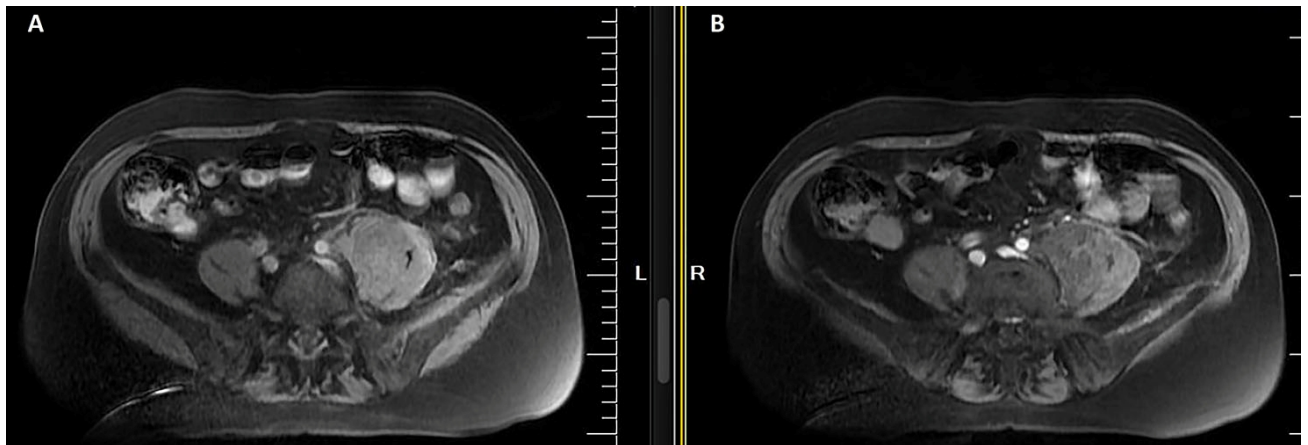


Figure 2. Axial T2 fat-suppressed images; without contrast media (A), high signals in left hemipelvic muscles and with contrast media (B), in left psoas muscle there are hypointense areas (indicates hemorrhage) with no contrast enhancement.

Discussion

Spontaneous hemorrhage is not a frequent complication of dermatomyositis or its treatment. Systemic causes include pregnancy, coagulation disorders, vasculitis (especially polyarteritis nodosa), renal artery

aneurysms, and renal artery malformations [6]. The clinical presentation may be acute or subacute, including the features described in our patients.

Langguth et al. [1] reported hemorrhagic myositis associated with heparin in a patient with dermatomyositis who developed aspiration pneumonia secondary to dermatomyositis-associated bulbar weakness. He received prednisone and unfractionated heparin po to protect against deep vein thrombosis and complained of a painful right hip 10 days later. A computed tomography (CT) scan showed hemorrhage in the rectus sheath and oblique muscles.

Microvascular injury is one of the complications in dermatomyositis. Kissel et al. [2]. found immune complexes in the wall of muscular arterioles and venules showing that complement is deposited and provoked to completion within the intramuscular microvasculature in patients diagnosed dermatomyositis. Other authors have reported that the capillaries are specific targets of the disease process [3]; a histopathological examination of the muscle specimen with minimal structural changes with focal capillary depletion and a significant decrease in capillary density. Electron microscopy of affected muscle prepares of patients with

dermatomyositis exhibited that nearly 50% reduction in the number of capillaries versus controls with other neuromuscular diseases [4]. In duration of inflammatory processes there are alterations in the endothelium of small arteries and capillaries, may results with thrombosis, vascular obstruction, ischemia, and necrosis, complicated with hemorrhage, ulceration or may perforation [7]. Orrell et al. [8] evaluated two patients with dermatomyositis with spontaneous hematoma without antithrombotic medicine. One had a massive rectus abdominis hematoma and abdominal-wall calcification, the other a spontaneous retroperitoneal hematoma.

In our patient, anticoagulant therapy was stopped one week before the left hip pain, because of the planning endoscopy, in order to investigate any malign process accompanied with dermatomyositis. However, unlike our patient it is probably that anticoagulant drugs that have to be taken because of other diseases, can be one of the reasons of the hemorrhage in patients with dermatomyositis.

References

1. Langguth DM, Wong RC, Archibald C, et al. Hemorrhagic myositis associated with prophylactic heparin use in dermatomyositis. *Ann Rheum Dis.* 2004;63:464–5.
2. Kissel JT, Mendell JR, Rammohan KW. Microvascular deposition of complement membrane attack complex in dermatomyositis. *N Engl J Med.* 1986;314:329–34.
3. Emslie-Smith AM, Engel AG. Microvascular changes in early and advanced dermatomyositis: a quantitative study. *Ann Neurol.* 1990;27:343–56.
4. Casademont J, Grau JM, Estruch R, et al. Relationship between capillary and muscle damage in dermatomyositis. *Int J Dermatol.* 1990;29:117–20.
5. Higashi Y, Mera K, Kanzaki T, et al. Fetal muscle hemorrhage attributable to heparin administration in a patient with dermatomyositis. *Clin Exp Dermatol.* 2009;34:448–9.
6. Swift DL, Lingeman JE, Baum WC. Spontaneous retroperitoneal hemorrhage: a diagnostic challenge. *J Urol.* 1980;123:577–82.
7. Eshraghi N, Farahmand M, Maerz LL, et al. Adult-onset dermatomyositis with severe gastrointestinal manifestations. Case report and review of the literature. *Surgery.* 1998;123:356–8.
8. Orrell RW, Johnston HM, Gibson C, et al. Spontaneous abdominal hematoma in dermatomyositis. *Muscle Nerve.* 1998;21:1800–3.