

Space-Occupying Lesions: Rare Causes Of Carpal Tunnel Syndrome

Yer Kaplayan Lezyonlar: Karpal Tünel Sendromunun Nadir Nedenleri

Raif Özden¹, İbrahim Gökhan Duman¹, Ömer Serkan Yıldız¹, Vedat Uruç¹,
Yunus Dođramacı¹, Erkam Kömürçü²

¹Mustafa Kemal Üniversitesi, Tıp Fakültesi, Ortopedi ve Travmatoloji AD., Hatay

²Çanakkale Onsekiz Mart Üniversitesi, Tıp Fakültesi, Ortopedi ve Travmatoloji AD., Çanakkale

Abstract

Most cases of carpal tunnel syndrome (CTS) are idiopathic. It is an extremely common entrapment neuropathy in the clinical practice. CTS caused by a tumor is a rare condition and it is more complicated than idiopathic CTS. Thus, the aim of our study is to evaluate the diagnosis and management of CTS caused by space-occupying lesions especially soft tissue tumors. CTS patients treated with surgery between 2004-2011 were included to the study. Of 410 patients, 12 were diagnosed as space occupying lesion. Patients with palpable mass or local swelling and neuropathy symptoms underwent magnetic resonance imaging (MRI) or ultrasonography for diagnosis. Complete excision of the tumors were performed. The symptoms subsided after surgery. CTS produced by a space-occupying lesion is uncommon and more difficult to treat than idiopathic CTS. Histopathologic examination revealed 1 tenosynovitis and tumors in 11 patients. The histopathological diagnosis of tumors were ganglion cysts in two, lipoma in five, lipofibromatous hamartoma in three, and hemangioma in one patient. In cases with unilateral CTS who had swelling or tenderness on the area of wrist, it is essential to achieve MRI, ultrasonography, and computed tomography alone or in combination in order to rule out space-occupying lesions around the carpal tunnel.

Key words: Carpal tunnel syndrome, tumors, space-occupying lesions.

Özet

Karpal tünel sendromu hastalığının nedeni çoğu zaman idiopattiktir. Son derece yaygın görülen bir tuzak nöropatisidir. Bir tümörün neden olduğu karpal tünel sendromu ise nadir görülen bir durumdur ve idiopatik karpal tünel sendromundan daha karmaşıktır. Bu çalışmanın amacı yer kaplayan lezyonların, özellikle de yumuşak doku tümörlerinin neden olduğu karpal tünel sendromunun tanı ve tedavisini değerlendirmektir. 2004-2011 yılları arasında cerrahi tedavi yapılan karpal tünel sendromlu hastalar çalışmaya dahil edildi. 410 hastanın 12'sinde yer kaplayan lezyon tespit edildi. Ele gelen kitle, lokal şişlik ve nöropati semptomları olan hastalara tanı için magnetik rezonans görüntüleme ve ultrasonografi yapıldı. Tümörlerin tamamı çıkarıldı. Ameliyat sonrası semptomlar geriledi. Yer kaplayan lezyonun neden olduğu karpal tünel sendromu, idiopatik karpal tünel sendromundan daha nadirdir ve tedavisi daha zordur. Histopatolojik incelemede 11 hastada tümör, 1 hastada tenosnovit saptandı. Tümörlerin histopatolojik tanısında ikisinde ganglion kisti, beşinde lipom, üçünde lipofibromatöz hamartom ve birinde hemanjiom saptandı. El bileğinde şişlik ve hassasiyet olan tek taraflı karpal tünel sendromu vakalarında yer kaplayan lezyonların tanısı için magnetik rezonans görüntüleme, ultrasonografi ve bilgisayarlı tomografi gibi tanı yöntemlerini tek tek yada kombine olarak kullanmak gerekir.

Anahtar kelimeler: Karpal tünel sendromu, tümör, yer kaplayan lezyon.

Background

Idiopathic CTS is the most common peripheral neuropathy. Although most cases are idiopathic, it may also associate with a number of systemic conditions, including diabetes

Sorumlu yazar / Corresponding Author: Raif Özden

Adres: Mustafa Kemal Üniversitesi Ortopedi ve Travmatoloji AD., Hatay

E-posta: raifozden@gmail.com

Geliş Tarihi / Received: 07.06.2014

Kabul Tarihi / Accepted: 09.07.2014

mellitus, rheumatoid arthritis, hypothyroidism, and pregnancy. Secondary compressive causes are rare. Among secondary causes, tumors are even rarer. CTS generally presents bilaterally and space-occupying lesions should be suspected in cases with unilateral symptoms, particularly with a long history and when the symptomatic hand displays severe neurologic impairment, while the contralateral hand is neurologically intact [1]. However, these space-occupying lesions are overlooked or misdiagnosed and treated as idiopathic CTS. It is known that there is an association between raised intracarpal canal pressure and clinical CTS. The raised pressure results from either an increase in content, or a decrease in size of the carpal canal, or combination of the two. In space occupying lesions of carpal canal one or both of these conditions can be seen but generally such factors are absent in most of the cases [2]. CTS due to mass effect is very unusual, however, there are reports of hypertrophy of tenosynoviums,[3] tumorous conditions,[4-6] tophaceous gout,[7-9] and malunion after distal radial fractures [10,11]. It is possible to detect space-occupying bony lesions with plain radiographs before surgery, but it is problematic to detect space occupying soft tissue tumors without particular physical examination. Thus, the aim of our study was to evaluate the diagnosis and management of CTS caused by space-occupying lesions especially soft tissue tumors.

Methods

A retrospective study was performed on a case series of 12 patients aged 19 to 63 years (mean age, 42.3 years) who underwent surgery for CTS due to space-occupying lesions. There were 3 men and 9 women. Volar lunate dislocations, malunion due to distal radial fracture, carpal bone fractures were excluded. The mean follow-up was 25 months (ranged 17 to 31). All patients had unilateral involvement. The diagnosis of carpal tunnel syndrome was made clinically and electrophysiologically. There was sensory loss in the distribution of the median nerve and weakness of the abductor pollicis brevis and of opposition of the thumb. Both of the Tinel's and Phalen's tests were positive. Nerve conduction studies were consistent with CTS. Examination of the patients with tumor revealed a soft non-fluctuant mass around the volar aspect of the wrist and/or hand.

In our institution, when a patient is clinically suspected of CTS, we do not routinely perform radiological tests (radiographs of carpal tunnel, posteroanterior, and lateral views) except the patients who has a history of distal radial fracture. In patients with swelling, palpable mass or tenderness on the region of wrist, plain radiographs, and ultrasonography and/or MRI were performed to exclude mass. Occasionally computed tomography was taken when the patients had a history of distal radial fracture. We performed open carpal ligament release and removed space-occupying lesions using the standard longitudinal incision. Sex and age were compared with patients who had idiopathic CTS. *Chi squared* test and *Mann-Whitney U* test were used.

Results

We performed surgery on 410 patients to treat CTS from February 2004 to October 2011. Of these patients 305 patients had bilateral and 105 patients had unilateral CTS. The preoperative physical examination revealed definite palpable mass or diffuse swelling at the volar aspect of the wrist in 12 patients. Under general anaesthesia, a longitudinal incision was made at the wrist. After dividing the transverse carpal ligament median nerve was detected. To simplify exploration, the incision was generally extended up to the middle or distal third of the forearm depending on the size of the mass. Following surgery, symptoms were resolved without recurrence or complications in all patients. The median nerve was compressed due to mass in the carpal canal. The types of lesions confirmed by histopathologic examination were as follows; ganglion cysts in two, lipoma in five, lipofibromatous hamartoma in three, hemangioma in one, and tenosynovitis in one patient. A detailed description of the causative factors is given on Table 1. There was no statistically significant difference in terms of gender and age between the two groups ($p > 0.05$).

All 5 lipoma cases showed clinically symptoms of CTS, on clinical examination there was a firm swelling in the palmar aspect of hand and wrist with well defined margins and tenderness (Figure 1a). Tinel sign and Phalen tests were positive. MRI study confirmed the diagnosis of a benign tumor, possibly lipoma, showing bright signal on T1 images (Figure 1b) and dark signals on fat suppressed images (Figure 1c). In these patients carpal tunnel was successfully

decompressed with a longitudinal incision (Figure 1d). Histopathologic examination showed a lipomatous tumor composed of mature adipocytes without intermingling nerve fibers. At 6 months after the excision, the numbness and pain had disappeared.

Table 1. Clinical features of the patients

Patient	Duration of symptoms (months)	Age	Sex	Diagnostic image	Diagnosis
1	16	56	M	MRI	Lipoma
2	12	52	F	MRI	Lipoma
3	14	63	F	MRI	Lipoma
4	6	55	F	MRI	Lipoma
5	17	49	F	MRI	Lipoma
6	13	29	M	MRI	LH
7	12	24	M	MRI	LH
8	24	25	M	MRI </td <td>LH</td>	LH
9	7	35	F	USG	Ganglion
10	11	19	F	USG	Ganglion
11	14	59	M	MRI	GR
12	18	42	F	MRI	Hemangioma

Lipofibromatous hamartoma: **LH**, Granulomatous reaction: **GR**, Ultrasonography: **USG**

Three patient diagnosed as CTS caused by lipofibromatous hamartoma revealed a soft, non-tender mass over the volar aspect of the wrist with no atrophy of the thenar eminence. There was no deficits in motor function affecting the hand. Altered sensation at the distribution of the median nerve was detected. Tinel's sign and Phalen's test were both positive. The MRI showed volar mass within the carpal tunnel which was firstly thought to be a ganglion cyst compressing the median nerve in one patient (Figure 2a,b, and c). Histological examination revealed non-neoplastic fibrofatty elements with mature fibrous and adipose tissue. Under general anaesthesia, a longitudinal incision was made at the wrist and the carpal tunnel was successfully decompressed (Figure 2d and e).

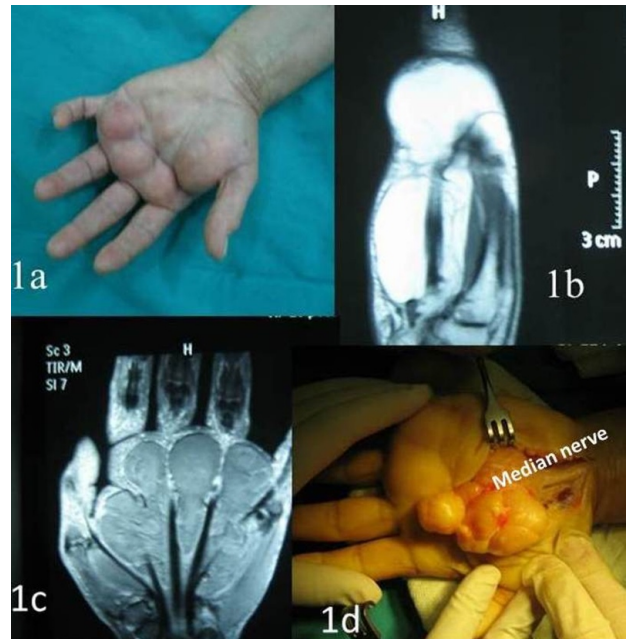


Figure 1.
a There is a firm swelling in the palmar aspect of left hand.
b Sagittal T1 weighted magnetic resonance image of left wrist demonstrating hyperintense signal of the lipoma.
c Dark signals on coronal fat suppressed images.
d Intraoperative photo showing the median nerve under lipoma.

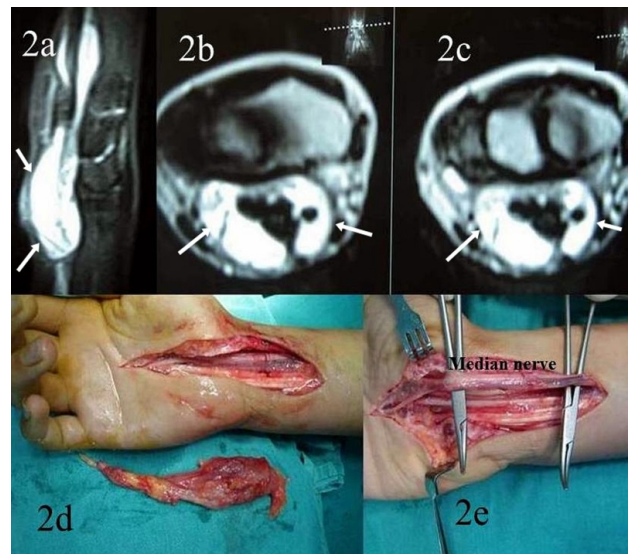


Figure 2. **a, b** and **c** Sagittal and axial magnetic resonance images of left wrist demonstrating hyperintense signal of the lipofibromatous hamartoma.
d The resected specimen show lipofibromatous mass was without an obvious capsule
e Intraoperative picture of of the median nerve after resection of the lipofibromatous hamartoma.

Two patients had CTS and a volar wrist ganglion. They were referred to our institute after the onset of symptoms. The physical examination showed hypoaesthesia in the median nerve distribution. There was no obvious thenar muscle atrophy or weakness of

palmar abduction of the thumb. There was swelling or tenderness on the area of wrist. We performed ultrasonography. Decompression and ganglion excision were performed (Figure 3a,b). After 16 months of the surgery, 2 patients noticed complete return of the sensation and resolution of the paresthesia.

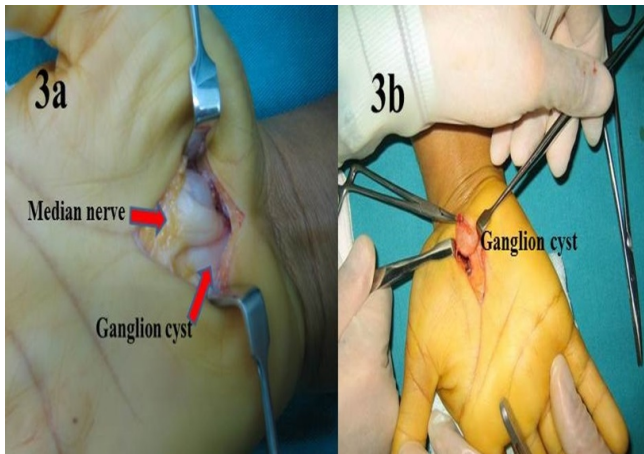


Figure 3.
a The ganglion was found under the median nerve in the carpal tunnel.
b Open carpal tunnel release with resection of the ganglion.

In one patient with CTS, MRI showed a mass around the median nerve (Figure 4a and b). Open longitudinal carpal ligament release was performed, and all the tissue was excised and a complete tenosynovectomy was performed (Figure 4c and d). Histologic examination of all the specimens showed granulomatous reaction (Figure 5). It was thought that it can be tuberculosis. However, in microbiological examination, mycobacterium tuberculosis was not cultured from the patient.

An another patient had a mass on the distal volar wrist. The mass had continued to grow progressively. On physical examination, the tumor was, soft, and tender. Patient had CTS symptoms. The results of electromyogram confirmed CTS. Plain X-ray revealed no specific findings. The clinical appearance was suggestive of lipoma of the right wrist but the MRI was reported as hemangioma (Figure 6a). Thus, open carpal tunnel release with resection of the mass was performed (Figure 6b). Histopathologic evaluation showed dilated and congested vascular structures in a fibrocollagenous stroma with region of

bleedings, consistent with of hemangioma. There has been no recurrence after 18 months of the operation.

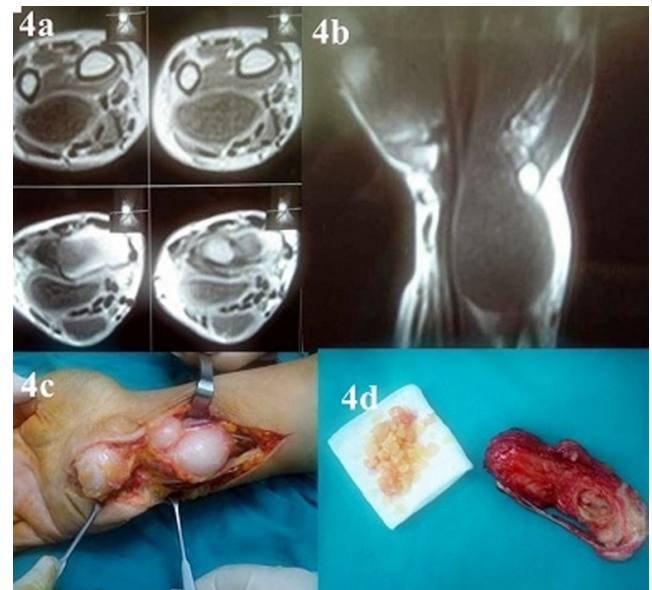


Figure 4.
a, b Axial and frontal magnetic resonance images of right wrist demonstrating hypointense signal of the mass.
c, d Intraoperative picture of lipofibromatous hamartoma of the median nerve.

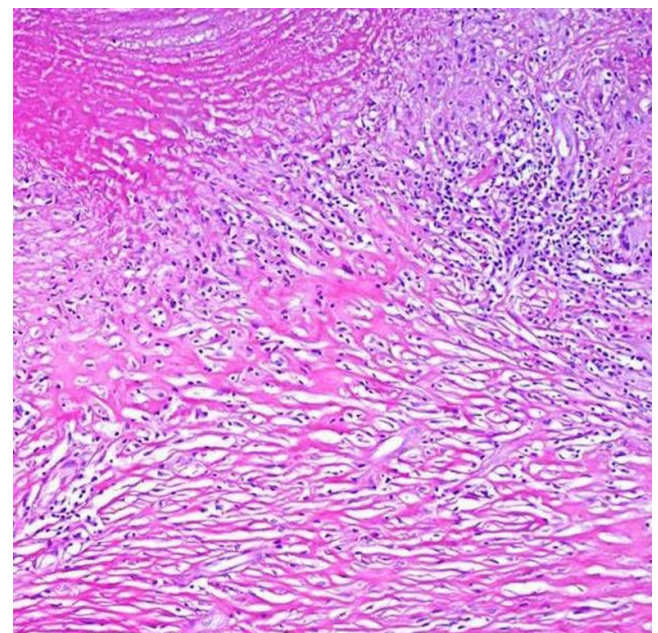


Figure 5. Microscopic view of the mass displaying granulomatous reaction (Hematoxylin-Eosin, x100).

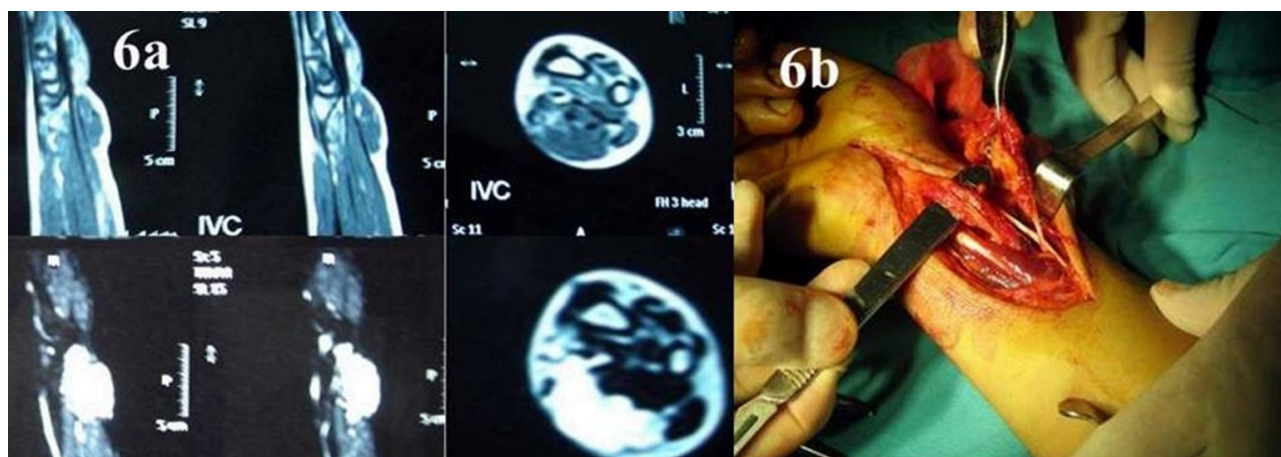


Figure 6. **a** MRI of hemangioma. Sagittal and axial images demonstrating an 3x3x1.5 cm lesion in the volar side of the wrist. **b** Macroscopic view of the hemangioma.

Discussion

CTS is known to be the most common compressive neuropathy in the hand. The carpal tunnel is a very small area containing of the fibrous tissue and carpal bones, where 9 flexor tendons and median nerve pass through. Although most cases of CTS are idiopathic, the rare identifiable causes could be the space-occupying lesions such as the swelling of tendon sheath, rheumatoid arthritis, distal radius fracture, volar dislocation of lunate, ganglion, lipoma, lipofibromatous hamartoma and gout. Systemic causes of the CTS are hypothyroidism, diabetes, acromegaly, amyloidosis, and pregnancy. If the space-occupying lesions are not detected or misdiagnosed and treated as idiopathic CTS, the patient's symptoms will not improve.

Idiopathic CTS usually occurs bilaterally. According to Padua et al.[12] bilateral impairment of median nerve is the rule in patients with CTS. Bagatur et al.[1,13] reported that CTS usually presents bilaterally and space-occupying lesions should be suspected in patients with unilateral symptoms, particularly with a long history and when the symptomatic hand shows severe neurophysiologic impairment, while the contralateral hand is neurophysiologically normal. In idiopathic CTS 66% of patients with unilateral CTS symptoms exhibit abnormal results in nerve conduction tests on contralateral hand. Thus, when patient has unilateral abnormalities, it is essential to suspect other reasons for CTS besides idiopathic CTS. Nakamichi and Tachibana[14] stated an increased incidence of space-

occupying lesions in unilateral CTS compared with bilateral CTS and concluded that when the condition is not bilateral and the aetiology is not obvious, a space-occupying lesion should be suspected. Despite the surgical treatment of CTS, some patients may still suffer from symptoms of CTS. When a physical examination shows swelling or tenderness around the wrist flexion creases, firstly carpal tunnel view test should be performed. Furthermore, if necessary, ultrasound is an ideal diagnostic test, especially for deeply located masses and can be used in such cases. MRI, however, provides more information about tumour type and anatomic relations and is so desirable for diagnostic precision and preoperative planning. Ultrasonogram has its advantages such as wide availability, lower cost, and shorter examination time. Additionally, accurate characteristics of cystic lesion can be identified by ultrasonogram. Thus, ultrasonogram was used in our study to detect ganglion cyst. CT scans are better than MRI regarding the detection of bony lesion. It is essential to perform these tests to identify the space-occupying lesion when unilateral CTS patients exhibit tenderness or swelling of volar wrist area [15,16].

Conclusions

As a conclusion in cases with unilateral CTS, and swelling or tenderness on the area of wrist, it is essential to achieve MRI, computed tomography, ultrasonography in combination or alone in order to rule out space-occupying lesions around the carpal tunnel.

References

1. Bagatur AE, Yalcinkaya M: Unilateral carpal tunnel syndrome caused by an occult palmar lipoma. *Orthopedics* 2009;32:10.
2. Bland JD: Carpal tunnel syndrome. *Curr Opin Neurol* 2005, 18:581-585.
3. Kang HJ, Park SY, Shin SJ, Kang ES, Hahn SB: Tuberculous tenosynovitis presenting as carpal tunnel syndrome. *J Korean Soc Surg Hand* 2000, 5:137-141.
4. Robinson AJ, Basheer MH, Herbert KJ: An unusual cause of carpal tunnel syndrome. *Plast Reconstr Aesthet Surg* 2010, 6:788-791.
5. Hankins CL: Carpal tunnel syndrome caused by a fibrolipomatous hamartoma of the median nerve treated by endoscopic release of the carpal tunnel. *J Plast Surg Hand Surg* 2012, 46:124-127.
6. Louaste J, Zejjari H, Chkoura M, Houmadi A, Rachid K: Carpal tunnel syndrome due to fibrolipomatous hamartoma of the median nerve. *Hand* 2011, 6:76-79.
7. Lin YC, Chen CH, Fu YC, Lin GT, Chang JK, Hu ST: Carpal tunnel syndrome and finger movement dysfunction caused by tophaceous gout: a case report. *Kaohsiung J Med Sci* 2009, 25:34-39.
8. Rich JT, Bush DC, Lincoski CJ, Harrington TM: Carpal tunnel syndrome due to tophaceous gout. *Orthopedics* 2004;27:862-863.
9. Chen CK, Chung CB, Yeh L, Pan HB, Yang CF, Lai PH, Liang HL, Resnick D: Carpal tunnel syndrome caused by tophaceous gout: CT and MR imaging features in 20 patients. *DAJR Am J Roentgenol* 2000, 175:655-659.
10. Bienek T, Kusz D, Cielinski L: Peripheral nerve compression neuropathy after fractures of the distal radius. *Hand Surg Br* 2006, 31:256-260.
11. Campbell D. Re: Peripheral nerve compression neuropathy after fractures of the distal radius. *Hand Surg Eur.* 2007, 32:233-234.
12. Padua L, Padua R, Nazzaro M, Tonali P: Incidence of bilateral symptoms in carpal tunnel syndrome. *J Hand Surg Br* 1998, 23:603-606.
13. Bagatur AE, Zorer G: The carpal tunnel syndrome is a bilateral disorder. *J Bone Joint Surg Br.* 2001, 83:655-658.
13. Nakamichi K, Tachibana S: Unilateral carpal tunnel syndrome and space-occupying lesions. *J Hand Surg Br* 1993, 18:748-749.
14. Horch RE, Allmann KH, Laubenberger J, Langer M, Stark GB: Median nerve compression can be detected by magnetic resonance imaging of the carpal tunnel. *Neurosurgery* 1997, 41:76-83.
15. Nakamichi K, Tachibana S: Ultrasonography in the diagnosis of carpal tunnel syndrome caused by an occult ganglion. *J Hand Surg Br* 1993, 18:174-175.