



Subclinical Hypothyroidism and Munchausen Syndrome: A Rare Entity

Subklinik Hipotiroidizm ve Munchausen Sendromu: Nadir Bir Birliktelik

Ermen KARAKILIÇ, Emre Sedar SAYGILI*, Hasan KAYA**, Erdal MERT***

Department of Endocrinology, Çanakkale Onsekiz Mart University Faculty of Medicine, Çanakkale, TURKEY

*Clinic of Endocrinology, Çanakkale Mehmet Akif Ersoy State Hospital, Çanakkale, TURKEY

**Department of Psychiatry, University of Health Sciences Ankara City Hospital, Ankara, TURKEY

***Department of Internal Medicine, Çanakkale Onsekiz Mart University Faculty of Medicine, Çanakkale, TURKEY

Abstract

Non-compliance to the prescribed levothyroxine (LT4) treatment is one of the reasons for the failure in managing hypothyroidism. This problem can usually be overcome by following the prescribed medication regimen. However, continuing disadherence for the purpose of misleading is called pseudomalabsorption. This makes LT4 absorption tests essential for an exact diagnosis. While patients diagnosed with pseudomalabsorption may have psychiatric disorders, cases with the diagnosis of a component of Munchausen syndrome are rare. Munchausen syndrome, also called factitious disorder, is a psychiatric disorder that characterizes recurring illness and misleading healthcare professionals. The primary motive of the patient is emotional attention which can demonstrate a chronic state. We present here an interesting case in which we diagnosed LT4 pseudomalabsorption as the cause of the failure in hypothyroidism management and detected other clinical symptoms of Munchausen syndrome such as unexplained skin wounds, falsified symptoms, and an excessive number of hospital admissions.

Keywords: Hypothyroidism; munchausen syndrome; pseudomalabsorption

Introduction

Munchausen syndrome (MS) characterizes falsified general medical symptoms or findings (1). Recently it has also been called factitious disorder (FD) imposed on self. The general feature of the disease is deception, often with an emotional motivation to attract

Özet

Hipotiroidizm yönetimindeki başarısızlığın nedenlerinden biri levotiroksin (LT4) tedavisine uyumsuzluktur. Bu problem genellikle ilacın uygun kullanımı ile aşılabılır. Bununla birlikte, psuedomalabsorpsiyon olarak isimlendirilen hastanın yanıltma amaçlı olarak ilaç alma uyumsuzluğuna devam etmesi tedavi başarısızlığını devam ettirebilir. Kesin bir teşhis yapmak için LT4 absorpsiyon testlerinin yapılması gerekecektir. Pseudomalabsorpsiyon tanısı konan hastalarda, psikiyatrik bozukluklar olabileceği belirtilmektedir ancak munchausen sendromu içerisinde tanı konulmuş vakalar nadirdir. Munchausen sendromu ya da diğer isimiyle faktisyöz bozukluk, hastanın yanıltıcı bulgularla sağlık çalışanlarını kandırmasıyla karakterize psikiyatrik bir bozukluktur. Hastanın temel motivasyonu duygusal kazançtır ve bu kronik bir durum gösterebilir. Burada, hipotiroidizm tedavisindeki başarısızlığın nedeni olarak LT4 psödomalabsorpsiyonu tanısı koyduğumuz, ardından munchausen sendromunun diğer klinik özelliklerini (açıklanamayan cilt yaraları, tekrarlayan kandırma amaçlı semptom ve bulgular ve aşırı sayıda hastane başvurusu gibi) saptadığımız ilginç bir vaka sunuyoruz.

Anahtar kelimeler: Hipotiroidi; munchausen sendromu; pseudomalabsorpsiyon

attention. Another form of FD involves imposing a disease on another person (e.g., the individual's child) to derive the same benefit (2).

The actual incidence of this disorder is difficult to measure due to poor reporting. Nevertheless, its frequency was 0.1% in the

Address for Correspondence: Ermen KARAKILIÇ, Department of Endocrinology, Çanakkale Onsekiz Mart University Faculty of Medicine, Çanakkale, TURKEY
Phone: ++905422809994 **E-mail:** Ermenkarakilic@comu.edu.tr

Peer review under responsibility of Turkish Journal of Endocrinology and Metabolism.

Received: 26 Dec 2020 **Received in revised form:** 15 Feb 2021 **Accepted:** 17 Feb 2021 **Available online:** 17 Mar 2021

1308-9846 / © Copyright 2021 by Society of Endocrinology and Metabolism of Turkey.
Publication and hosting by Türkiye Klinikleri.

This is an open access article under the CC BY-NC-SA license (<https://creativecommons.org/licenses/by-nc-sa/4.0/>)

general population, while higher rates were reported in clinical conditions (3). Identification of FDs depends on detailed systematic information about a patient's medical record. The patients can produce non-existent symptoms or signs and sometimes aggravate existing symptoms. They may trigger seizures by not taking anticonvulsants or hypoglycemia due to the overuse of hypoglycemic drugs. Clinical findings can be very multiple and novel (4). In a review, it was stated that MS patients mostly applied with endocrine disorders (4). Factitious thyrotoxicosis due to excessive LT4 intake has been known for many years (5). However, only a few cases relate MS with hypothyroidism (6). Although in compliance to LT4 treatment for deception is often reported as pseudomalabsorption, this situation generally does not associate with MS (7-10). In refractory primary hypothyroidism, TSH remains above the normal range although the LT4 dose exceeds 1.9 mcg/kg/day (11). In the absence of any known cause for malabsorption, and if patients state that they are compatible with the drug, the diagnosis of pseudomalabsorption and LT4 absorption test should be considered. The LT4 absorption test is safe and easily applicable to confirm the diagnosis of pseudomalabsorption (7). We present here an interesting non-healing case of subclinical hypothyroidism with in-

teresting MS clinical findings like non-healing skin wounds, primary polydipsia, and excessive hospital admissions.

Case Report

A 21-year-old female was hospitalized because of high TSH levels despite using 750 mcg/day LT4. She had been diagnosed with hypothyroidism at the age of 15. Although the LT4 dose was increased over the years, the TSH level was above the target value and rarely decreased to normal levels (Figure 1). Physical examination of the patient revealed slightly dry skin and abdominal obesity, and she had about 2 × 2 cm ulcers on both right and left thigh (Figure 2, Figure 3). The remaining systemic examination was normal.

The anti-TPO antibody was negative, and TSH was 7.5 uIU/mL with an intake of 750 mcg LT4 with normal free T4 (fT4). Ultrasonography revealed normal thyroid volume and parenchyma with an isoechoic nodule of 2 cm in the right lobe. She had adequate iodine intake, and no other cause of hypothyroidism could be identified. Fine needle aspiration biopsy (FNAB) of the nodule conducted last year was reported as benign. Anti-gliadin and endomysium, and transglutaminase antibodies were negative. LT4 absorption test was performed due to unexplained high amount of LT4 requirement. The patient was asked to fast

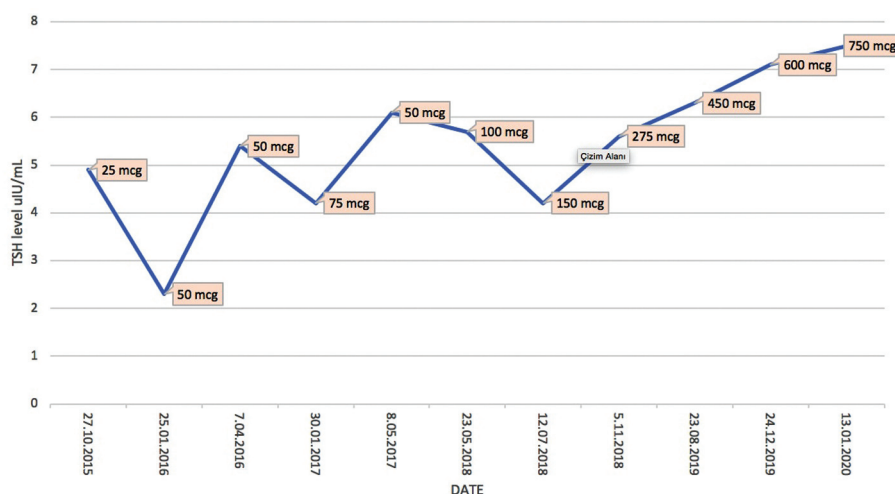


Figure 1. TSH results measured over time and levothyroxine dose prescribed at that time.

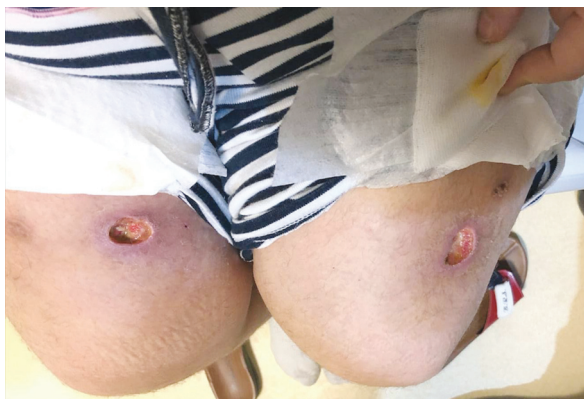

Figure 2. Skin wounds on both thighs of the patient.

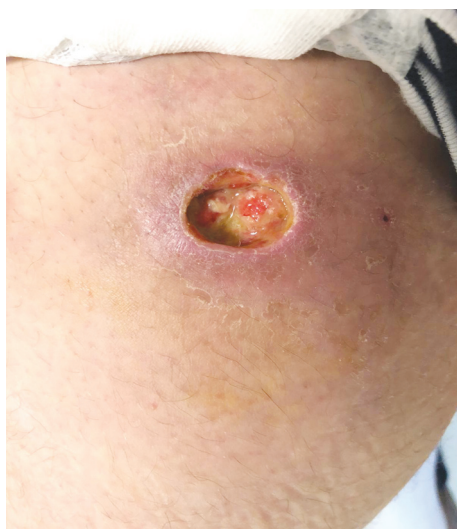

Figure 3. Skin wound on the left thigh.

overnight, then 1000 µg of LT4 was administered, and the oral cavity was inspected, and behavior was observed for 90 min. FT4 increased from 1.1 ng/dL (0.9-1.7 ng/dL) to 2.9 ng/dL in 4 h gradually (Figure 4). To confirm the diagnosis, rapid test was combined with a long LT4 absorption test. The patient was given 600 mcg of LT4 once a week for four weeks. After LT4 intake, the patient was kept under observation for 2 h. At the end of four weeks, the TSH level was 1 uIU/mL.

The patient stated that skin wounds on thighs occurred just before the hospitalization, and she had similar skin wounds previously, but the exact diagnosis could not be made. The culture study of the ulcer confirmed *Staphylococcus aureus* colonization. Clindamycin and anti-septic spray treatment

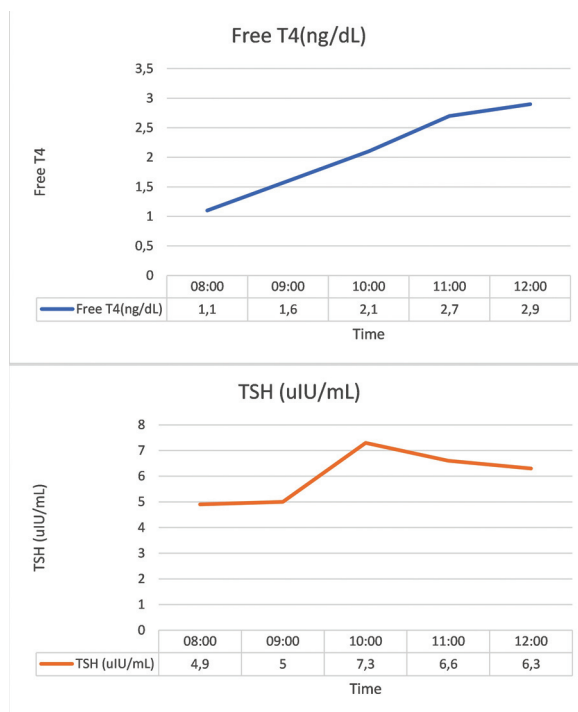


Figure 4. Results of rapid absorption test.

were started. Pathological examination of the punch biopsy revealed only non-specific inflammatory findings, and it was not diagnostic. Despite daily dressing and antibiotic treatment, the size of the ulcer remained the same and did not regress despite a 2-month follow-up. Despite all diagnostic tests, management strategies, and follow-up, the department of infectious diseases and dermatology could not make a diagnosis. On checking the patient's health records, the number of hospital admissions was found to be quite high. We found 465 admissions to six different health institutions in the last five years. Moreover, these numbers did not include that of primary care admissions. Hospitalization records stated that she did not want to be discharged during hospitalization. Hospital admissions were for 14 different departments with different complaints. Often, the patient applied to the hospital with some non-healing complaints such as bruising around the chin or shoulder pain. For these complaints, many advanced and sometimes repetitive diagnostic tests were performed. However, her complaints did not seem to improve and could not be diagnosed exactly.

The previous notes of the endocrinology department stated that she persistently insisted on having a thyroidectomy for the thyroid nodule, despite the benign results of FNAB. Although the patient was informed that thyroid hormone replacement was insufficient despite high doses and that the problem would be more serious after thyroidectomy, she was very insistent for surgery.

Another reason for her previous hospital admission was polydipsia. In the last two years, the water consumption of the patient had increased and was 15 liters a day. She was hospitalized last month for a thirst test. The test was compatible with primary polydipsia.

A psychiatric evaluation revealed that she expressed herself mainly due to somatic complaints and had no anxiety or depressive disorders. In her anamnesis, she stated that her family relations were not good, especially; her father displayed an aggressive attitude. She stated that as a child, she was frequently sick and had scoliosis surgery ten years ago; her admissions to the hospital gradually increased after this operation.

While investigating the patient due to insufficient LT4 replacement, recognizing unexplained skin ulcers, abnormally high number of hospital admissions, and repetitive non-healing previous complaints, a diagnosis of "Munchausen Syndrome" was made on psychiatric evaluation.

Discussion

Munchausen Syndrome can occur with very different clinical pictures. A primary characteristic of MS is deception, and unlike malingering, there is no obvious external gain. The main motivation is often the desire to focus attention on oneself. Patients are often women, and the disorder usually begins before the age of 20 (12). In our case, the patient was a woman in her early twenties, and the disease seems to be triggered after a scoliosis operation. The primary motivation of the patient was emotional needs, and she was very happy with the attention she received from healthcare workers.

While patients present a disease or symptom that never really occurred, they can also exaggerate the findings of an already existing disease (12). Complaints of endocrine disor-

ders are often observed in MS patients (4). Factitious thyrotoxicosis and hypoglycemia are the most common (5). However, only one case was reported that related FD with hypothyroidism (6).

In the current case, hypothyroidism was diagnosed about six years ago and, the TSH level generally remained in the subclinical range since the diagnosis. An increase in fT4 after the rapid LT4 absorption test was compatible with pseudomalabsorption (8). We extended the test by giving 600 mcg LT4 once a week under observation. TSH levels normalized, and there was no real malabsorption (9,10).

All the diagnostic approaches, including punch biopsy, could not diagnose, and the clinic of skin ulcers could not conform to a particular disease. Failure of diagnosis and the non-healing nature of skin wounds were compatible with the MS diagnosis.

She was also compatible with the diagnosis of FD imposed on self as per DSM-5 criteria: induction of disease, complaints about the inability to heal, no obvious material gain is known as a result of the deception behavior, and no other mental illness was diagnosed (1).

Another typical feature of MS is frequent admission to health institutions (4). Four-hundred sixty-five hospital admissions of the patient in the last five years were not normal. Similar to this case, some patients with MS can present with complaints of repeated bruising or recurrent pain. Over time, complaints of the patient may differ or the same complaint may be repeated many times (12,13). The diagnosis of primary polydipsia in our patient may be a finding related to this disorder, although it has not been reported earlier before.

The possible MS is first noticed by a non-psychiatric physician. The group should be accompanied by a psychiatrist to discuss the diagnosis, laboratory findings, and signs with the patient, in a process defined as supportive confrontation. It should be emphasized in a supportive confrontation that the patient needs help and must be assured that the care will continue. Follow-up with a multi-disciplinary team including both medical and psychological support has developed positive results in such cases (14).

Our case demonstrates that the clinical pictures of MS can be quite different. Patients with hypothyroidism which does not improve despite high dose LT4 should be examined for pseudomalabsorption, and if supportive findings are also observed, the exact diagnosis may be MS.

Source of Finance

During this study, no financial or spiritual support was received neither from any pharmaceutical company that has a direct connection with the research subject, nor from a company that provides or produces medical instruments and materials which may negatively affect the evaluation process of this study.

Conflict of Interest

No conflicts of interest between the authors and / or family members of the scientific and medical committee members or members of the potential conflicts of interest, counseling, expertise, working conditions, share holding and similar situations in any firm. Written informed consent was taken from the patient for the publication of this case report and concomitant images.

Authorship Contributions

Idea/Concept: Ersen Karakılıç, Erdal Mert, Emre Serdar Saygılı; Design: Ersen Karakılıç, Emre Serdar Saygılı, Erdal Mert; Control/Supervision: Ersen Karakılıç, Emre Serdar Saygılı, Erdal Mert; Data Collection and/or Processing: Ersen Karakılıç, Erdal Mert, Hasan Kaya; Emre Serdar Saygılı, Erdal Mert, Hasan Kaya; Analysis and/or Interpretation: Emre Serdar Saygılı, Erdal Mert, Hasan Kaya; Literature Review: Ersen Karakılıç, Erdal Mert, Hasan Kaya; Writing the Article: Ersen Karakılıç, Erdal Mert, Hasan Kaya; Critical Review: Ersen Karakılıç, Erdal Mert, Hasan Kaya; References and Fundings: Ersen Karakılıç, Erdal Mert, Emre Serdar Saygılı, Hasan Kaya; Materials: Ersen Karakılıç, Erdal Mert, Emre Serdar Saygılı, Hasan Kaya.

References

1. American Psychiatric Association. Diagnostic and Statistical Manual of Mental Disorders, Fifth Edition (DSM-5), American Psychiatric Association 2013, Arlington, VA. [\[Link\]](#)
2. Kinns H, Housley D, Freedman DB. Munchausen syndrome and factitious disorder: the role of the laboratory in its detection and diagnosis. *Ann Clin Biochem.* 2013;50:194-203. [\[Crossref\]](#) [\[PubMed\]](#)
3. Catalina ML, Gómez Macias V, de Cos A. Prevalence of factitious disorder with psychological symptoms in hospitalized patients. *Actas Esp Psiquiatr.* 2008;36:345-349. [\[PubMed\]](#)
4. Yates GP, Feldman MD. Factitious disorder: a systematic review of 455 cases in the professional literature. *Gen Hosp Psychiatry.* 2016;41:20-28. [\[Crossref\]](#) [\[PubMed\]](#)
5. Vorasart P, Sriphrapadang C. Factitious thyrotoxicosis: how to find it. *Diagnosis (Berl).* 2020;7:141-145. [\[Crossref\]](#) [\[PubMed\]](#)
6. Molines L, Fromont I, Morlet-Barla N, Nogueira JP, Valéro R, Vialettes B. Pseudomalabsorption de L-thyroxine: une forme de pathomimie [L-thyroxine pseudomalabsorption: a factitious disease]. *Presse Med.* 2007;36:1390-1394. French. [\[Crossref\]](#) [\[PubMed\]](#)
7. Gonzales KM, Stan MN, Morris JC 3rd, Bernet V, Castro MR. The Levothyroxine Absorption Test: A Four-Year Experience (2015-2018) at The Mayo Clinic. *Thyroid.* 2019;29:1734-1742. [\[Crossref\]](#) [\[PubMed\]](#)
8. Soares RMV, de Figueiredo RM, Melo Dantas MN, Solano Brito MV, Pires Sousa AG, da Câmara VL, Coelho Nóbrega LH, Lima JG; Rapid levothyroxine absorption test for diagnosis of It4 pseudomalabsorption: Case report and proposal of a cutoff point. *J Endocrinol Diabetes Obes.* 2016;4:1083. [\[Link\]](#)
9. Khaled A, Sulaiman A, Seong KC, John H M. Thyroxine absorption test. *Biomed J Sci &Tech Res.* 2018;3:3171-3174; BJSTR.MS.ID.000881. [\[Link\]](#)
10. Walker JN, Shillo P, Ibbotson V, Vincent A, Karavitaki N, Weetman AP, Wass JA, Allahabadia A. A thyroxine absorption test followed by weekly thyroxine administration: a method to assess non-adherence to treatment. *Eur J Endocrinol.* 2013;168:913-917. [\[Crossref\]](#) [\[PubMed\]](#)
11. Centanni M, Benvenga S, Sachmechi I. Diagnosis and management of treatment-refractory hypothyroidism: an expert consensus report. *J Endocrinol Invest.* 2017;40:1289-1301. [\[Crossref\]](#) [\[PubMed\]](#) [\[PMC\]](#)
12. Ring HC, Miller IM, Benfeldt E, Jemec GBE. Artefactual skin lesions in children and adolescents: review of the literature and two cases of factitious purpura. *Int J Dermatol.* 2015;54:e27-32. [\[Crossref\]](#)
13. Bass C, Wade DT. Malingering and factitious disorder. *Pract Neurol.* 2019;19:96-105. [\[Crossref\]](#) [\[PubMed\]](#)
14. Eisendrath SJ, Feder A. Management of factitious disorders. In: Feldman M, Eisendrath S, eds. *The spectrum of factitious disorders.* 1st. Washington, DC: American Psychiatric Press; 1996:195-213.