

Limb Ischemia Associated With Covid-19 and Its Treatment With Above-Knee Amputation

The International Journal of Lower
Extremity Wounds
2022, Vol. 21(2) 197–200
© The Author(s) 2021
Article reuse guidelines:
sagepub.com/journals-permissions
DOI: 10.1177/15347346211063257
journals.sagepub.com/home/ijl



Alaaddin Oktar Üzümcügil¹ , Nihat Demirhan Demirkiran² ,
Süleyman Kaan Öner² , Alper Akkurt² , and Sevil Alkan Çeviker³ 

Abstract

An 84-year-old male patient with no known comorbidity was admitted to the emergency department with complaints of dyspnea and respiratory distress. The patient was referred to the COVID outpatient clinic, laboratory and radiology tests were performed. Thoracic CT scan of the patient showed large peripheral patchy ground glass densities observed in the lower lobes of both lungs. CT imaging findings were evaluated by an experienced radiologist and reported as COVID-19 pneumonia. The patient, who was self-isolated at home for 5 days, presented to the emergency department again on the fifth day with complaints of respiratory distress, fever, bruising with cough, and loss of peripheral pulse in the left lower extremity. Necessary tests were performed on the patient. An above-knee amputation was performed when a diagnosis of limb ischemic necrosis was made and no revascularization attempt was considered by the CVS department. This case study describes the coexistence of sudden lower extremity thrombosis and Covid-19 in our case without a known chronic disease.

Keywords

arterial/ischaemic, lower extremity wound, venous surgery, wound management, limb circumference measurements, wound assessment, health related quality of life assessments, wound assessment

Introduction

Coronavirus disease (COVID-19), caused by a novel coronavirus (SARS-CoV-2), is a highly contagious disease that was first announced in Wuhan, Hubei province of China in December 2019. COVID-19 is deemed as a pandemic by WHO in March 2020, and now represents an unprecedented public health crisis of global proportions.^{1,2} To date, the pandemic has affected 174,593,253 people worldwide.³ In Turkey, 5,300,236 infected patients and 48,341 deaths have been reported as of 08/06/2021.⁴

The main symptoms of COVID-19 are known as fever, dry cough and respiratory distress.^{5,6} However, as the number of treated patients increase; our experience and knowledge regarding the disease also widened. Recently much attention has been paid to the neurologic, nephrologic and thrombotic complications of COVID-19.⁷⁻¹⁰

Severe coronavirus disease 2019 (COVID-19) is often complicated with coagulopathy, markedly elevated D-dimer was related to poor prognosis of end-stage disease.¹⁰⁻¹² However, the severity of these thrombotic complications is not well elucidated. Acute lower extremity ischemia (ALI) is a vascular emergency which may lead to devastating complications unless urgently treated. The association between COVID and peripheral coagulopathies has attracted attention lately.¹³⁻¹⁵

In the following case, we report a patient with limb ischemia associated with COVID-19 and its treatment with above-knee amputation.

Case Report

An 84-year-old male patient without any additional known comorbidities presented to the emergency department with complaints of shortness of breath and respiratory distress. His vital findings were recorded as SPO2: 90, fever: 38.2 C, TA: 120/80 mm Hg, and pulse: 76/min. The patient was directed to the COVID outpatient clinic, where laboratory and radiology tests were conducted. Thoracic CT scan of the patient revealed patchy ground-glass densities with extensive peripheral location which are observed in lower lobes of both lungs. The patient did not have pain and tenderness in the lower extremity.

¹Kutahya Park Hayat Hastanesi, Kutahya, Turkey

²Kutahya Health Sciences University, Kutahya, Turkey

³Çanakkale Onsekiz Mart University, Medicine, Çanakkale, Turkey

Corresponding Author:

Alaaddin Oktar Üzümcügil, M.D, Assist. Prof. Dr, Department of Orthopaedics and Traumatology, Kutahya Park Hayat Hastanesi, Kutahya, 43040, Turkey.

Email: alaaddinoktar.uzumcugil@ksbu.edu.tr

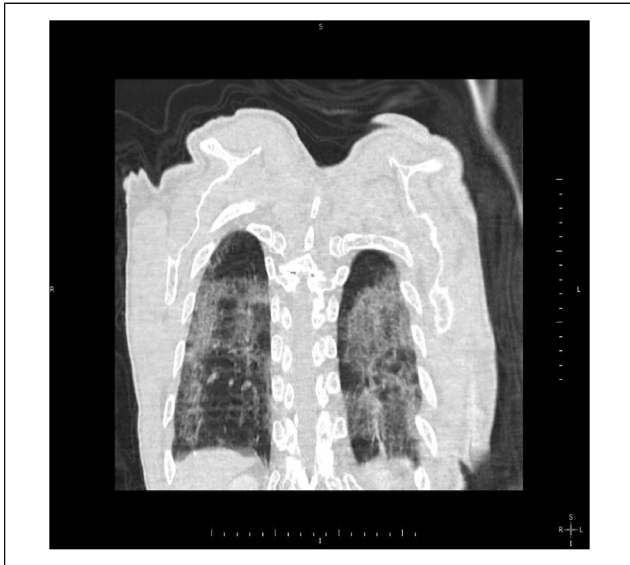

Figure 1. Thoracic CT scan imaging findings indicating COVID-19 pneumonia. Note the patchy ground-glass densities with extensive peripheral location in lower lobes of both lungs.

The CT imaging findings were evaluated by an experienced radiologist and reported as COVID-19 pneumonia.(Figure 1) Laboratory findings were also indicative (Crp: 54 mg/L, Wbc: 7400 uL, Lymphocyte: 1560 uL, D-Dimer: 730 ng/ml, Fibrinogen:425 mg/dl). A nasopharyngeal swab sample was sent for PCR analysis. Although the PCR test resulted negative, the patient was diagnosed as COVID-19 pneumonia treatment according to guidelines of the Ministry of Health was initiated. The patient was then discharged with COVID pneumonia treatment including oseltamivir, azithromycin, cefdinir and paracetamol.

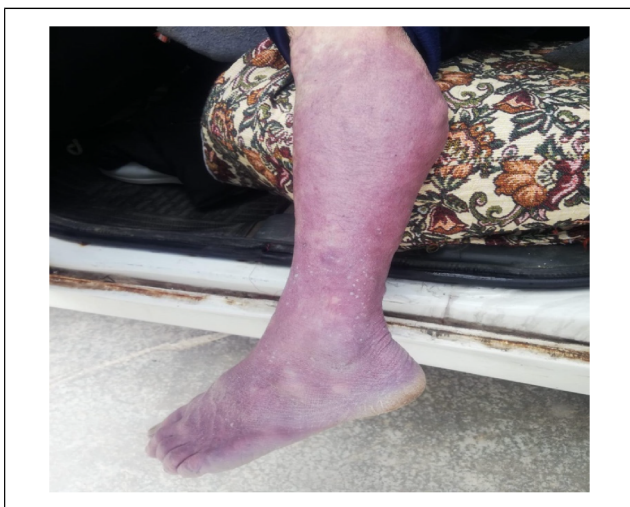

Figure 2. Appearance of the left lower extremity with cyanosis and loss of peripheral pulses at emergency department.

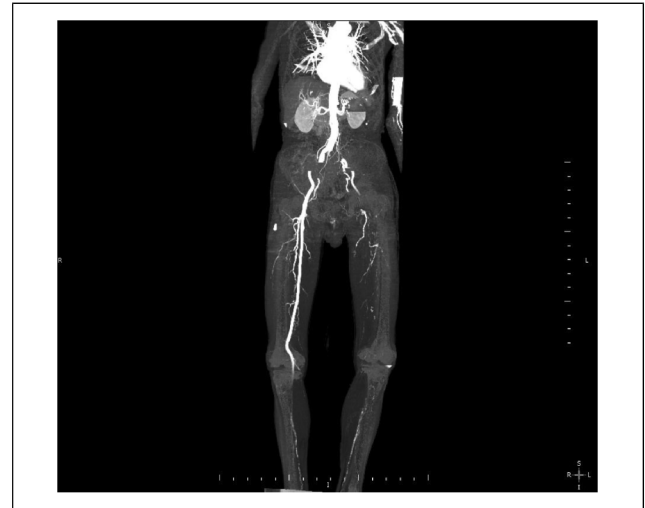

Figure 3. Angio-CT sections of the patient revealed no contrast filling was observed in the common femoral, superficial femoral, popliteal arteries and trifurcation in the left lower extremity.

After self-isolation at home conditions for 5 days, the patient referred to the emergency department again with breathing difficulties, fever, cough along with cyanosis and loss of peripheral pulses on left lower extremity.(Figure 2) He has no spontan pain on left lower extremity. Radiology tests were repeated and the presence of peripherally located ground glass densities on both x-ray, and thorax CT showed advanced ground-glass opacities with extended peripherally located subpleural areas in both lungs, and are reported as typical for coronavirus infection. Also, an angio-CT was ordered to evaluate the peripheric circulation.

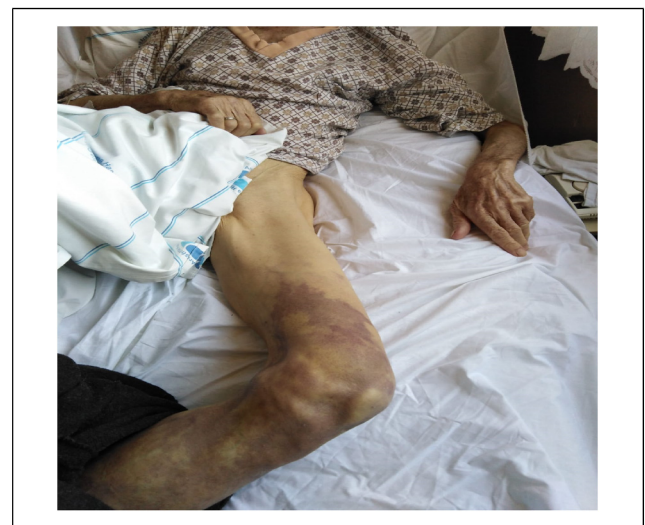

Figure 4. Appearance of the left lower extremity demonstrated cyanosis with distinct boundaries above knee level.

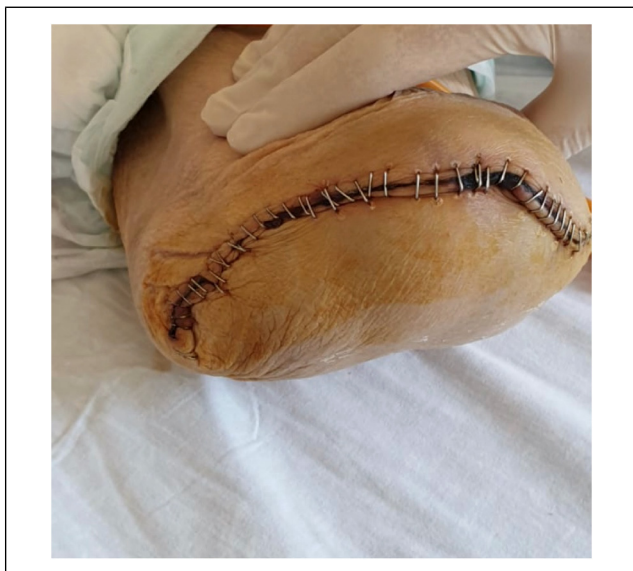

Figure 5. No wound complications were observed during inpatient follow-up period.

No contrast filling was observed in the common femoral, superficial femoral, popliteal arteries and trifurcation in the left lower extremity on contrasted lower extremity angio-CT. (Figure 3) The patient was admitted to the COVID ward and consulted with cardiovascular surgery (CVS) and orthopedics departments. Orthopedic physical examination revealed pain on left extremity above knee level. An asymmetrical appearance between legs was noticed, the left calf was colder when compared with the right side; and developed cyanosis with distinct boundaries (Figure 4). As the limb ischemic necrosis diagnosis was achieved, and no revascularization interventions were considered by CVS department, an above-knee amputation was planned. Because of the localization of necrosis in the affected extremity, cardiovascular surgeons did not plan thrombolectomy and thrombus aspiration.

The patient was operated after necessary precautions were taken and all recommended personal protective equipment for the orthopedic and trauma surgeon were complied. Amputation of the left lower extremity above the demarcation line was performed and the patient was followed in the COVID ward. No wound or general complications were observed and the patient was discharged after successful treatment of his pneumonia. (Figure 5).

Discussion

The association between COVID-19 and hypercoagulability has been recently reported in preliminary observations.¹³⁻¹⁵ Abnormal laboratory coagulation tests, specifically elevated D-dimer and fibrin degradation products, have been related to higher mortality rates in COVID-19 patients.⁹

The pathomechanism of thromboembolic events observed in COVID patients remains unclear. However, non-respiratory components usually observed in COVID-19 patients including arterial and venous thromboembolism, high blood pressure nephrologic and neurologic disorders have been attributed to the endothelium damage caused by the virus.¹⁶ Another possible explanation of thrombotic events in COVID-19 is the systemic proinflammatory cytokine response, which increases procoagulant factors, local inflammation, and hemodynamic alterations thus leading to atherosclerosis.¹⁷ Also, last but not the least mechanism may be attributed to angiotensin-converting enzyme 2 (ACE) receptors.^{18,19} ACE receptors are expressed on vascular muscle membranes and have been held responsible as the entry receptor for the COVID-19 virus.

Regardless of the pathologic mechanism, the thrombotic complications and the risk of limb ischemic necrosis should be closely evaluated and monitored in COVID-19 patients. Prophylactic and therapeutic protocols to prevent these devastating vascular complications should be developed and implemented.

Author Contributions

AOÜ: Surgery, wrote. NDD: Writing, design. SKÖ: Surgery, wrote. AA: Surgery, writing. SAÇ: Wrote, design, planning.

Declaration of Conflicting Interests

The author(s) declared no potential conflicts of interest with respect to the research, authorship, and/or publication of this article.

Funding

The author(s) received no financial support for the research, authorship and/or publication of this article.

Ethical Approval


Not applicable, because this article does not contain any studies with human or animal subjects.


ORCID iD

Alaaddin Oktar Üzümcügil  <https://orcid.org/0000-0001-7220-5206>

Nihat Demirhan Demirkiran  <https://orcid.org/0000-0002-0724-9672>

Süleyman Kaan Öner  <https://orcid.org/0000-0002-4333-0582>

Alper Akkurt  <https://orcid.org/0000-0001-8261-0678>

Sevil Alkan Çeviker  <https://orcid.org/0000-0003-1944-2477>

Supplemental Material

Supplemental material for this article is available online.

References

1. Perini P, Nabulsi B, Massoni CB, Azzarone M, Freyrie A. Acute limb ischemia in two young, non-atherosclerotic patients with COVID-19. *The Lancet*. 2020;395(10236):1546.
2. World Health Organization. *Coronavirus disease 2019 (COVID-19) situation report—51*. World Health Organization; 2020. https://www.who.int/docs/default-source/coronaviruse/situationreports/20200311-sitrep-51-covid-19.pdf?sfvrsn=1ba62e57_10
3. <https://www.worldometers.info/coronavirus/> (08/06/2021)
4. [https://covid19.saglik.gov.tr/\(08/06/2021\)](https://covid19.saglik.gov.tr/(08/06/2021))
5. <https://www.cdc.gov/coronavirus/2019-ncov/symptoms-testing/symptoms.html> (08/06/2021)
6. Singhal T. A review of coronavirus disease-2019 (COVID-19). *The Indian Journal of Pediatrics*. 2020;87(4):281–286.
7. Mao L, Jin H, Wang M, et al. Neurologic manifestations of hospitalized patients with coronavirus disease 2019 in Wuhan, China. *JAMA Neurol*. 2020;77(6):683–690.
8. Farina M, Barbisoni F, Bertacchini S, et al. An account of the first hours of the covid-19 epidemic at the nephrology unit in lodi (Lombardy). *Giornale Italiano di Nefrologia: Organo Ufficiale Della Societa Italiana di Nefrologia*. 2020;37(2).
9. Han H, Yang L, Liu R, et al. Prominent changes in blood coagulation of patients with SARS-CoV-2 infection. *Clinical Chemistry and Laboratory Medicine (CCLM)*. 2020;1(ahead-of-print).
10. Bikdeli B, Madhavan MV, Jimenez D, et al. COVID-19 and thrombotic or thromboembolic disease: implications for prevention, antithrombotic therapy, and follow-up. *J Am Coll Cardiol*. 2020;75(23):2950–2973.
11. Tang N, Bai H, Chen X, Gong J, Li D, Sun Z. Anticoagulant-treatment is associated with decreased mortality in severe coronavirus disease 2019 patients with coagulopathy. *Journal of Thrombosis and Haemostasis*. 2020;18(5):1094–1099.
12. Huang C, Wang Y, Li X, et al. Clinical features of patients infected with 2019 novel coronavirus in wuhan, China. *The Lancet*. 2020;395(10223):497–506.
13. Bellosta R, Luzzani L, Natalini G, et al. Acute limb ischemia in patients with COVID-19 pneumonia. *Journal of Vascular Surgery*. 2020;72(6):1864–1872.
14. Qian SZ, Pan JY. COVID-19 with limb ischemic necrosis. *Journal of Cardiothoracic and Vascular Anesthesia*. 2020;34(10):2846–2847.
15. Perini P, Nabulsi B, Massoni CB, Azzarone M, Freyrie A. Acute limb ischaemia in two young, non-atherosclerotic patients with COVID-19. *The Lancet*. 2020;395(10234):1417–1418.
16. Varga Z, Flammer AJ, Steiger P, et al. Endothelial cell infection and endotheliitis in COVID-19. *The Lancet*. 2020;395:1417–1418.
17. Zhou F, Yu T, Du R, et al. Clinical course and risk factors for mortality of adult inpatients with COVID-19 in wuhan, China: a retrospective cohort study. *Lancet* 2020;395:1054–1062.
18. Leung JM, Yang CX, Tam A, et al. ACE-2 expression in the small airway epithelia of smokers and COPD patients: implications for COVID-19. *European Respiratory Journal*. 2020.
19. Bean D, Kraljevic Z, Searle T, et al. Treatment with ACE-inhibitors is associated with less severe disease with SARS-covid-19 infection in a multi-site UK acute Hospital Trust. *MedRxiv*. 2020.